

Case Report

Hyperbaric oxygen therapy for interstitial cystitis resistant to conventional treatments

Tomoaki Tanaka¹, Hidenori Kawashima¹, Tetsuya Makino¹, Sadanori Kamikawa³, Noboru Kato² and Tatsuya Nakatani¹

¹Department of Urology, ²Critical Care Medicine, Osaka City University Graduate School of Medicine, and ³Department of Urology, Osaka City General Hospital, Osaka, Japan

Abstract: We treated two cases of interstitial cystitis (IC) that were resistant to some conventional therapies with hyperbaric oxygen (HBO). Both patients underwent 20 sessions of 100% oxygen inhalation (2.0 atmosphere absolute for 60 min/day × 5 days/week for 4 weeks) in a hyperbaric chamber. The period of follow up was 12 months for case 1 and 9 months for case 2. After a course of HBO, the bladder mucosal ulcer (Hunner's ulcer) disappeared, and changes from baseline in pain and urinary frequency was constitutively inhibited. There were no adverse events during the 20 treatment sessions. One woman (case 1) had mild Eustachian tube dysfunction, resulting in a transient hearing impairment. HBO seems to be an option for treatment of IC resistant to conventional therapies.

Key words: Hunner's ulcer, hyperbaric oxygen, interstitial cystitis, visual analog scale.

Introduction

Interstitial cystitis (IC) is a collective term, including a variety of clinical findings. In view of definite symptoms, the term 'painful bladder syndrome' is more adequate. Only 10–50% of IC patients demonstrate a classical mucosal ulcer (Hunner's ulcer) and most of them are diagnosed as the result of some positive factors and exclusions.^{1,2} Regrettably, the etiology of IC remains unclear. Many options for the treatment of IC have been proposed, while the suitable therapy has yet to be defined from clinical evidence.^{3–5} Hyperbaric oxygen (HBO) therapy has been used mainly on the patients with hemorrhagic cystitis or radiation cystitis and has gained recognition during the last 15 years.^{6–9} Especially, chronic radiation cystitis sensitive to HBO is almost equivalent to IC regarding clinical conditions and histological alterations. In those bladder diseases, there are both ischemia and a reduction in bladder capacity due to fibrosis of the bladder wall.^{10–12} Thus, we have planned and conducted a pilot study of HBO in two IC patients. We got the approval from the ethics committee of our institute and the informed consent from the patients before starting HBO therapy.

Case report

Case 1

A 79-year-old woman with IC had undergone hydrodistension (80 cmH₂O) three times at our department since she had been diagnosed with IC in January 2004. After the first hydrodistension, the intravesical instillation of heparin (10 000 IU × 2 times/week for 15 weeks) was added. Transient palliation of urgency, urinary frequency and pelvic pain was seen, but the duration of effectiveness was decreased as repeating hydrodistension. The cystoscopic examination

revealed a Hunner's ulcer and severe glomerulations on a distended bladder mucosa. We treated the patient with HBO (2.0 atmosphere absolute [ATA] for 60 min/day × 5 days/week for 4 weeks) immediately after the fourth hydrodistension in December, 2004. HBO treatment achieves a decrease of urinary frequency and pelvic pain. The daily voiding frequency decreased from a baseline range of 25 to a range of 8, 9 and 9 times per day at 1, 3 and 9 months follow up, respectively (Table 1). The patient reported an improvement on the pain scale from the baseline of 100 mm to a range of 30, 35 and 40 mm at 1, 3 and 9 months follow up, respectively (Table 1). Initially, a baseline range of functional bladder capacity was 30 mL. HBO therapy resulted in a bladder capacity ranging 100–150 mL at 1, 3 and 9 months follow up (Table 1). Furthermore, HBO treatment achieved a significant amelioration of both glomerulations and Hunner's ulcer on endoscopic findings (Fig. 1a,b). The patient had mild Eustachian tube dysfunction during HBO treatment, resulting in a transient hearing impairment. Conservative medication was required for this condition. At 12 months after HBO treatment, the remission of symptoms appeared (Table 1). We are proposing a second HBO or other options for IC.

Case 2

A 61-year-old woman was diagnosed with IC at another hospital in January, 2005. Simultaneously, the patient underwent hydrodistension and laser ablation for mucosal ulcer, but symptoms were not improved. Then, other conventional treatments (e.g. intravesical instillation of heparin, non-steroidal anti-inflammatory drugs [NSAIDs] and IPD) were not effective for this patient's condition. In particular, the patient was treated with the continuous epidural analgesia against extreme pelvic pain associated with bladder filling. On endoscopic findings, there were moderate glomerulations and a Hunner's ulcer on bladder mucosa. We treated with HBO treatment under the same conditions as case 1 in April 2005. HBO treatment resulted in a decrease of urinary frequency and pelvic pain. Furthermore, the range of functional bladder capacity was increased from 80 mL before treatment to 150 mL at 1 month follow up. Those changes in symptoms from baseline have been sustained for 8 months (Table 1).

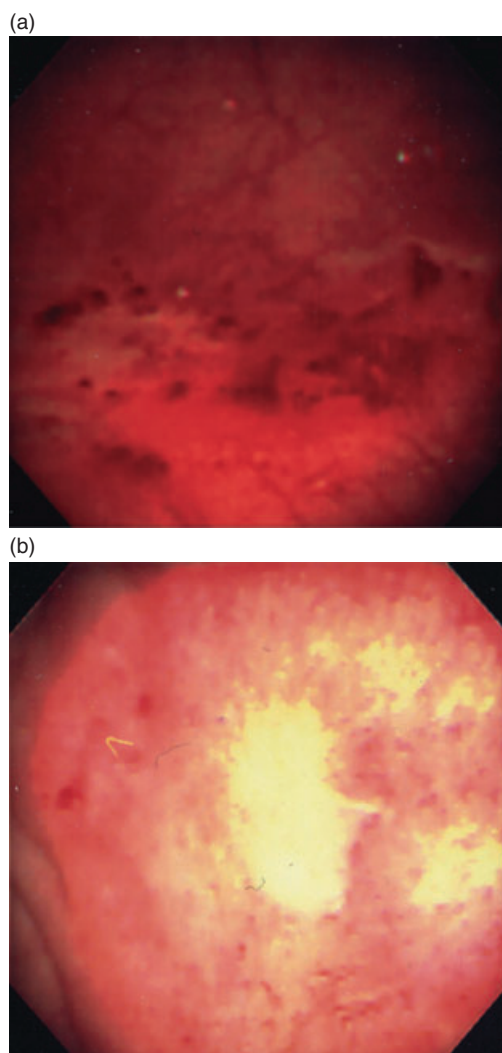
Correspondence: Tomoaki Tanaka, MD, PhD, Department of Urology, Osaka City University Graduate School of Medicine, 1-4-3 Asahimachi, Abenoku, Osaka 545-8585, Japan. Email: tomoaki826@msic.med.osaka-cu.ac.jp

Received 27 February 2006; accepted 18 May 2006.

Table 1 Change in clinical symptoms during a period of follow up

Parameter	Case	Baseline	Follow up			
			1 month	3 months	9 months	12 months
Urinary frequency in a day	1	25	8	9	9	15
	2	21	12	10	10	–
Nocturia	1	12	3	2	3	7
	2	8	4	3	2	–
Bladder capacity (mL)	1	30	150	120	136	55
	2	80	130	168	187	–
Pain (mm on VAS)	1	100	30	35	42	70
	2	70	30	30	15	–

VAS, visual analog scale.

**Fig. 1** Cystoscopic findings revealed the bladder mucosal disease before and after HBO treatment. (a) Hunner's ulcer (b) Granulation in an ulcerative region.

Discussion

The biological mechanism of HBO originated from hypersaturating oxygen dissolved in plasma due to treatment. This phenomenon results in an increased diffusion gradient between the circulation and surrounding tissues, forcing oxygen into the damaged hypoxic urothelial tissues. Subsequently, HBO treatment stimulates leukocyte function characterized by phagocytosis, producing growth factors that enhance angiogenesis.⁶ Finally, healthy granulation tissue grows at the local sites.⁸ HBO therapy has been mainly available for chronic radiation cystitis and hemorrhage cystitis since 15 years ago.^{6–9} In particular, chronic radiation cystitis represents some histological alterations including submucosal hemorrhage, interstitial fibrosis and smooth muscle fibrosis,¹⁰ which correspond to IC.^{11,13} According to those findings, we postulated that HBO could be an effective option for IC with typical cystoscopic findings (glomerulations, Hunner's ulcer and interstitial fibrosis). The two cases we treated with HBO showed a significant decrease of urinary frequency and pelvic pain, along with an increase of bladder capacity. Furthermore, the effects in symptoms have been sustained for several months. Recently, van Ophoven *et al.* has reported a pilot study of HBO for six IC patients.¹⁴ They suggested that there was no difference between the classical type and the non-ulcerative type of IC regarding effectiveness of HBO. A larger, randomized clinical trial will be needed to define criteria of HBO for IC patients. HBO therapy is well tolerated. Adverse events, including visual disturbance, Eustachian tube dysfunction and claustrophobia are unusual.¹⁵ Furthermore, the advantage of HBO is non-invasive nature compared with hydrodistension¹³ or intravesical instillation of dimethylsulfoxide (DMSO).¹⁶

The present two cases suggest that HBO could be used for treatment of IC patients resistant to conventional therapies.

References

- 1 Koziol JA. Epidemiology of interstitial cystitis. *Urol. Clin. North Am.* 1994; **21**: 7–20.
- 2 Pecker R, Fall M. Toward a precise definition of interstitial cystitis: further evidence of differences in classic and nonulcer disease. *J. Urol.* 2002; **167**: 2470–2.

- 3 Peeker R, Fall M. Treatment guidelines for classic and non-ulcer interstitial cystitis. *Int. Urogynecol. J. Pelvic Floor Dysfunct.* 2000; **11**: 23–32.
- 4 Fall M, Baranowski AP, Fowler CJ *et al.* EAU guidelines on chronic pelvic pain. *Eur. Urol.* 2004; **46**: 681–9.
- 5 Peeker R, Fall M. Interstitial cystitis – a time for revision of name and diagnostic criteria in the new millennium? *BJU Int.* 2002; **89**: 637–8.
- 6 Hader JE, Marzella L, Myers RA, Jacobs SC, Naslund MJ. Hyperbaric oxygen treatment for experimental cyclophosphamide-induced hemorrhagic cystitis. *J. Urol.* 1993; **149**: 1617–21.
- 7 Norkool DM, Hampson NB, Gibbons RP, Weissman RM. Hyperbaric oxygen therapy for radiation-induced hemorrhagic cystitis. *J. Urol.* 1993; **150**: 332–4.
- 8 Weiss JP, Mattei DM, Neville EC, Hanno PM. Primary treatment of radiation-induced hemorrhagic cystitis with hyperbaric oxygen: 10-year experience. *J. Urol.* 1994; **151**: 1514–17.
- 9 Furness PD III, Palmer LS, Palmer JS, Capelli-Schellpfeffer M, Cheng EY. Hyperbaric oxygen therapy for pediatric hemorrhagic cystitis. *J. Urol.* 1999; **161**: 1596–7.
- 10 Crew JP, Jephcott CR, Reynard JM. Radiation-induced haemorrhagic cystitis. *Eur. Urol.* 2001; **40**: 111–23.
- 11 Irwin P, Galloway NT. Impaired bladder perfusion in interstitial cystitis: a study of blood supply using laser Doppler flowmetry. *J. Urol.* 1993; **149**: 890–2.
- 12 Pontari MA, Hanno PM, Ruggieri MR. Comparison of bladder blood flow in patients with and without interstitial cystitis. *J. Urol.* 1999; **162**: 330–4.
- 13 Lavelle JP, Meyers SA, Ruiz WG, Buffington CA, Zeidel ML, Apodaca G. Urothelial pathophysiological changes in feline interstitial cystitis: a human model. *Am. J. Physiol. Renal Physiol.* 2000; **278**: F540–53.
- 14 van Ophoven A, Rossbach G, Oberpenning F, Hertle L. Hyperbaric oxygen for the treatment of interstitial cystitis: long-term results of a prospective pilot study. *Eur. Urol.* 2004; **46**: 108–13.
- 15 Capelli-Schellpfeffer M, Gerber GS. The use of hyperbaric oxygen in urology. *J. Urol.* 1999; **162**: 647–54.
- 16 Rossberger J, Fall M, Peeker R. Critical appraisal of dimethyl sulfoxide treatment for interstitial cystitis: discomfort, side-effects and treatment outcome. *Scand. J. Urol. Nephrol.* 2005; **39**: 73–7.